

Lapachol Administered to Rats (*Rattus norvegicus* Berkenhout, 1769): Teratogenic or embryotoxic?

Juliana Corrêa do Carmo Cancino¹, Vera Maria Peters¹, Ivone Antonia de Souza², Marcos Antônio Fernandes Brandão³, Luciana Valente Borges^{1,4} & Martha de Oliveira Guerra^{1*}

¹ Centro de Biologia da Reprodução, Universidade Federal de Juiz de Fora, Campus da UFJF – C. P. 328, CEP 36.001-970, Juiz de Fora MG, Brazil.

² Universidade Federal de Pernambuco, Recife, PE, Brazil.

³ Faculdade de Farmácia e Bioquímica, Universidade Federal de Juiz de Fora, Juiz de Fora, MG, Brazil.

⁴ Programa de Pós-Graduação em Patologia, Universidade Federal Fluminense, Niterói, RJ, Brazil

* Corresponding author: R. São Mateus, Nº 187, Apto. 801, São Mateus, CEP: 36.025-001, Juiz de Fora, MG, Brazil; Tel.: 55-32-32293251; Fax: 55-32-32293255. E-mail: martha.guerra@ufjf.edu.br

Abstract. Due to the controversy in literature regarding embryotoxic and teratogenic effects of lapachol, the present work aimed to investigate the consequences of the administration of this drug (100 and 200 mg/kg) to pregnant Wistar rats on the ninth day post-coitum, in order to assess its maternal and fetal toxicity. Maternal data indicate that the dose of 100 mg/kg of lapachol was not toxic, whereas the dose of 200 mg/kg produced a light toxicity, establishing the dose limit for developmental toxicity assessment. Both doses caused fetal body weight reduction and resorptions, but no malformations. Hence our studies suggest an embryotoxic effect but no teratogenicity of lapachol in Wistar rats.

Key words: embryotoxicity, lapachol, rat.

Resumo. Lapachol administrado a ratas (*Rattus norvegicus* Berkenhout, 1769): Teratogênico ou embriotóxico? Devido a controvérsias na literatura sobre os efeitos embriotóxicos e teratogênicos do lapachol, o presente trabalho teve como objetivo investigar as conseqüências da administração desta droga (100 and 200 mg/kg) a ratas Wistar prenhes no nono dia pós-coito, para investigar sua possível toxicidade no organismo materno e fetal. Dados maternos indicaram que na dose de 100 mg/kg o lapachol não foi tóxico. Enquanto que na dose de 200 mg/kg induziu uma leve toxicidade, estabelecendo a dose limite para a avaliação da toxicidade do desenvolvimento. As duas doses causaram redução de peso corporal e reabsorções, mas não causaram malformações. Assim, este estudo sugere um efeito embriotóxico, mas não teratogênico do lapachol em ratas Wistar.

Palavras-chaves: embriotoxicidade, lapachol, rato.

INTRODUCTION

The extrapolation of the results obtained in animal reproductive toxicology studies to the actual reproductive risks to human beings is very controversial, particularly when it is known that no experimental animal model is in fact hardly adequate. Therefore the assessment of human reproductive risks is based on epidemiological and experimental data. The most relevant findings regarding the assessment of developmental toxicity are: embryo loss

in the pre implantation period, resorptions, dead fetuses, alterations in embryo fetal growing and malformations. The ranking of hazard levels depends on malformation, surviving and growing data during the period of embryo and fetal development (KHERA *et al.*, 1989).

Reproductive toxicology studies on the teratogenicity of lapachol [2-hydroxy-3-(3-methyl-2-butenyl)-1,4-naphthoquinone] (Fig.1), a phytotherapy compound from the Bignoneaceae family (genus *Tabebuia*), with a wide therapeutical spectrum (AUSTIN, 1974; DUARTE *et al.*, 2000; LIMA *et*

al., 2002; SACAÚ, *et al.*, 2003; DE ANDRADE-NETO *et al.*, 2004; LIMA *et al.*, 2004; BALASSIANO *et al.*, 2005), are controversial. Lapachol was considered embryotoxic by two groups – Almeida *et al.* (1988) and Guerra *et al.* (1999, 2001), whereas only Almeida's group demonstrated its teratogenicity.

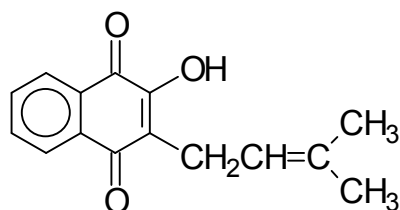


Figure 1. Lapachol [2-hydroxy-3-(3-methyl-2-butenyl)-1,4-naphthoquinone]

Almeida *et al.* (1988) treated pregnant rats from the seventh until the twelfth day of pregnancy (presence of spermatozoa in vaginal smear = day one post-coitum) with 100 mg/kg body weight of lapachol. They found 78.7% resorptions and the following malformations: exophthalmia and cleft lips. At the dose level of 500 mg/kg body weight, they also found celosomy, besides the above mentioned malformations. Guerra *et al.* (1999 and 2001), after administration of 100 and 200 mg/kg body weight to rats in the same period of gestation (8-12 days post-coitum), found 99 and 100% of lethality, respectively, but no malformations.

Mazoni (1998) administered 50 mg/kg body weight of lapachol to pregnant rats from the eighth to the twelfth day post-coitum, killed the animals on the 21st day of gestation, and observed that, at this dose level, lapachol did not cause a significant number of deaths among the fetuses of treated mothers, but caused body weight reduction of the fetuses – control: 3.69 ± 0.48 (110); vehicle (50% hydroalcoholic solution): 3.45 ± 0.29 (100); lapachol: 2.83 ± 0.60 (108) (data expressed in mean \pm standard deviation, fetal absolute weight (g), $p < 0.05$). External malformations were not observed in the examined fetuses.

According to what Manson and Kang (1994) preconized, the reduction of a substance concentration or its administration on a single critical day of pregnancy is a useful tool to elucidate the

possible teratogenic effects of drugs. As the reduction of lapachol concentration administered to pregnant rats resulted in absence of fetal deaths in a significant level and did not show teratogenicity (MAZONI *et al.*, 1998), this work aims at presenting another approach to assess malformations, through exposing pregnant rats to lapachol on the ninth day post-coitum, a critical day for the rat embryo development.

MATERIAL AND METHODS

Plant material

Lapachol, obtained from *Tabebuia ochracea*, was purchased from PVP Pharmaceutic Laboratory (Piauí state, Brazil) with 63% purity, and then processed by the Quality Control Laboratory of the Pharmacy and Biochemistry Faculty, Federal University of Juiz de Fora (UFJF), yielding 98% purity.

Animals

Adult Wistar rats, obtained from the vivarium of Center of Biology of Reproduction (Federal University of Juiz de Fora, MG, Brazil), were housed individually under standard laboratory conditions on light-darkness cycles of 12 h and controlled temperature. Animal care and the experimental protocol followed the principles and guidelines suggested by the Brazilian College of Animal Experimentation (COBEA) and were approved by the Ethical Committee of the Federal University of Juiz de Fora (UFJF) (protocol numbers 38/2003 and 40/2003-CEA).

Males of proved fertility inseminated the females and the presence of spermatozoa in the vaginal smear characterized the first post coitum day (DPC).

Test protocol

Animals received the same doses of lapachol that had previously demonstrated its embryo lethal effect (GUERRA *et al.*, 1999; 2001) – 100 and 200 mg/kg body weight, in a single dose on the ninth day post-coitum.

In the studies carried out by Guerra *et al.* (1999; 2001), lapachol was dissolved in a hydroalcoholic solution (50% pure alcohol and 50% distilled water). Since alcohol 'per se' is embryotoxic, another experimental group was added in this work, in which a higher concentration of lapachol was dissolved in

tween-80 solution (a drop of tween + a drop of absolute alcohol in 1ml of distilled water).

The animals were distributed into six groups:

- Control (C): 100 mL of distilled water (n = 10);
- Vehicle (V): 1 mL of hydroalcoholic solution (n = 11);
- Lapachol 100 (L100): 100 mg/kg of lapachol dissolved in 1 mL of hydroalcoholic solution (n = 10);
- Lapachol 200 (L200): 200 mg/kg of lapachol dissolved in 1 mL of hydroalcoholic solution (n = 12);
- Tween-80 (T80): 1 mL of tween solution (n = 5);
- Lapachol 200 (LT200): 200 mg/kg of lapachol dissolved in tween-80 solution (n = 6).

Initially, the rats were observed during 60 minutes after the administration of the substances and, later, twice a day, for detection of clinical signs of toxicity, such as piloerection, diarrhea, vaginal bleeding and increased or decreased activity in the cage. Food consumption was monitored daily; body weight was measured every three days, including the treatment (ninth day post-coitum) and the euthanasia days (before and after the reproductive tract removal) (CHRISTIAN *et al.*, 2001).

Euthanasia was carried out by cervical dislocation under anesthesia (ketamine + xylazine) on the 21st day post-coitum. After laparotomy, maternal organs were examined, and liver and kidneys were dissected out, weighed and fixed in buffered formalin for later histopathological analysis. The reproductive tract was exposed and removed altogether. Implantations were counted from right to left ovaric edge of the uterine horn.

A longitudinal section was made in the uterine horns in order to record the number of live (those that responded with movement when touched with tweezers) and dead fetuses, and early or late resorptions. Ovaries were dissected out, weighed and the number of *corpora lutea* was recorded.

Fetuses and placenta were dissected out, and each fetus underwent an external examination for the detection of malformations. The litter was then weighed (fetuses and placenta), and the average weight of fetus and placentae per litter was obtained. Two thirds of the fetuses were autopsied for removal of the kidneys, liver, lungs and brain, which were weighed individually and per litter.

Statistical analysis

The data were processed by one-way analysis of variances (ANOVA), followed by Bonferroni's test, for normal distribution. Discontinued data or proportions were analyzed using the qui-square or Kruskal-Wallis' test. Level of significance $\alpha = 0.05$.

RESULTS

Clinical signs of maternal toxicity, such as piloerection, hypo or hyperactivity, diarrhea and vaginal bleeding, were not observed.

Although there are some punctual differences in food consumption, these were of no biological significance (data not shown).

Maternal autopsy did not reveal any important alterations.

Body weight on the 1st and the 21st day post-coitum, the weight of liver, kidneys (absolute and relative) and ovaries, and number of corpora lutea and implantations are shown in table 1.

Rats treated with the hydroalcoholic solution of L200 presented smaller body weight when compared to the other groups. Liver absolute and relative weights of L200 and LT200 rats were significantly smaller when compared to the other groups ($p < 0.05$).

Histopathological analysis of maternal liver and kidneys did not show any important alterations (results not shown). The other variables did not show any significant differences.

The mean of corpora lutea / rat, total number of implantations, resorptions and live fetuses per experimental group, and the implantation index are shown in table 2.

In group L200 (n=12), five mothers showed resorption of the entire litter and seven had some fetuses with body weight reduction. In group LT200, no live fetus was found.

The weights of placenta, fetal body and organs (absolute and per litter), except for groups L200 and LT200, are expressed in table 3.

None of the externally examined fetuses presented cleft lip, celosomy, exophthalmia, or any other important external morphological alteration.

Table 1. Maternal variables in control (C), vehicle (V - hydroalcoholic solution), lapachol 100 mg (L100) and 200 mg (L200) dissolved in hydroalcoholic solution, vehicle (T80 - tween-80) and lapachol - 200 mg, dissolved in tween-80 (LT200).

Variables	C (n = 10)	V (n = 11)	L 100 (n = 10)	L 200 (n = 12)	T80 (n = 5)	LT200 (n = 6)
Implantations	102	104	101	129	46	68
Resorptions	0	3	29	107	1	68
Living fetuses	102	101	72	22	45	0
% resorptions / group	0	2.9	28.7	82.9	2.2	100
% of live fetuses / group	100	99	71.3	21.8	99	0
Corpora lutea mean ^a	11.9 ± 1.4	11.8 ± 1.2	11.2 ± 1.4	11.8 ± 1.2	10.4 ± 1.5	12.0 ± 1.1
Implantation index ^a	86.0 ± 10.7	80.5 ± 18.6	88.1 ± 11.1	89.0 ± 14.3	86.2 ± 13.4	92.7 ± 11.8

^a p<0.05, data are expressed as mean ± standard deviation.

Table 2. Total number of implantations, resorptions, live fetuses; proportion of resorptions and of live fetuses (%); index of implantation in control (C), vehicle (V - hydroalcoholic solution), lapachol 100 mg (L100) or 200 mg (L200) dissolved in hydroalcoholic solution, vehicle (T80 - tween-80) and lapachol 200mg dissolved in tween-80 (LT200).

Variables	C (n = 10)	V (n = 11)	L 100 (n = 10)	L 200 (n = 12)	T80 (n = 5)	LT200 (n = 6)
Implantations	102	104	101	129	46	68
Resorptions	0	3	29	107	1	68
Living fetuses	102	101	72	22	45	0
% resorptions / group	0	2.9	28.7	82.9	2.2	100
% of live fetuses / group	100	99	71.3	21.8	99	0
Corpora lutea mean ^a	11.9 ± 1.4	11.8 ± 1.2	11.2 ± 1.4	11.8 ± 1.2	10.4 ± 1.5	12.0 ± 1.1
Implantation index ^a	86.0 ± 10.7	80.5 ± 18.6	88.1 ± 11.1	89.0 ± 14.3	86.2 ± 13.4	92.7 ± 11.8

^a (Total number of implantations / total number of corpora lutea) X 100.

Table 3. Body, placenta and fetal organ weights expressed as absolute weight, weight per litter and relative weight, in control (C), vehicle (V), lapachol 100 mg (L100) and tween-80 (T80) groups.

Variables	C	V	L100	T80
Absolute weight				
Body (g)	3.43 ± 0.33 (91)	3.49 ± 0.30 (93)	2.92 ± 0.34 (60) ^a	3.44 ± 0.005 (45)
Placenta (g)	0.44 ± 0.06 (91)	0.45 ± 0.06 (93)	0.46 ± 0.09 (60) ^a	0.48 ± 0.06 (45)
Kidneys (mg)	22.00 ± 2.46 (90)	21.90 ± 2.89 (92)	18.28 ± 2.54 (60)	22.41 ± 2.43 (29)
Liver (mg)	288.33 ± 30.17 (91)	299.44 ± 31.99 (93)	255.78 ± 31.67 (60)	288.57 ± 32.98 (30)
Lungs (mg)	110.03 ± 14.22 (91)	110.45 ± 17.43 (93)	99.62 ± 15.60 (60)	108.90 ± 14.01 (29)
Brain (mg)	160.70 ± 12.94 (91)	157.91 ± 9.89 (93)	142.35 ± 10.05 (60)	147.30 ± 13.74 (30)
Weight per litter				
Body (g)	3.44 ± 0.20 (10)	3.48 ± 0.18 (11)	2.85 ± 0.31 (10) ^a	3.42 ± 0.30 (5)
Placenta (g)	0.44 ± 0.04 (10)	0.45 ± 0.05 (11)	0.46 ± 0.05 (10)	0.48 ± 0.03 (5)
Kidneys (mg)	22.00 ± 1.41 (10)	21.91 ± 1.87 (11)	18.20 ± 1.93 (10)	22.40 ± 1.82 (5)
Liver (mg)	289.90 ± 20.19 (10)	300.38 ± 23.07 (11)	252.90 ± 24.61 (10)	285.60 ± 32.73 (5)
Lungs (mg)	111.90 ± 8.75 (10)	112.36 ± 12.22 (11)	100.30 ± 11.40 (10)	109.60 ± 9.86 (5)
Brain (mg)	161.30 ± 6.27 (10)	156.55 ± 6.22 (11)	141.20 ± 6.58 (10)	147.20 ± 10.96 (5)
Relative weight				
Kidneys (mg)	6.45 ± 0.40 (10)	6.30 ± 0.290 (11)	6.33 ± 0.521 (10)	6.60 ± 0.30 (5)
Liver (mg)	84.55 ± 5.07 (10)	86.19 ± 3.19 (11)	88.50 ± 4.71 (9)	83.82 ± 2.84 (5)
Lungs (mg)	32.45 ± 2.75 (10)	31.92 ± 2.41 (11)	35.27 ± 4.48 (9)	31.70 ± 1.61 (5)
Brain (mg)	47.40 ± 2.91 (10)	45.26 ± 2.46 (11)	49.47 ± 3.58 (9)	43.48 ± 3.63 (5)

Groups treated with L200 did not have enough fetuses for analysis. Data are expressed as mean ± standard deviation (n); ^a p<0.05.

DISCUSSION

In embryotoxicity studies, it is necessary to separate direct toxicity on the fetus, from secondary effects as a consequence of maternal toxicity, since the latter alone is able to cause alterations in embryo morphogenesis (KHERA, 1984). Signs commonly used to assess maternal toxicity are: body weight decrease, food and water consumption, clinical signs, organs toxicity and maternal mortality (CHAHOUH *et al.*, 1999).

Clinical signs of toxicity, such as piloerection, diarrhea, vaginal bleeding, locomotor alterations among others, were not observed in any of the rats. Maternal data indicate that the dose of 100 mg/kg body weight of lapachol does not present toxic effects detectable through the experimental approach used. Animals treated with higher doses of a hydroalcoholic solution of lapachol, presented body weight reduction, whereas liver absolute and relative weight of L200 and LT200 treated rats were significantly smaller than that of the other groups ($p < 0.01$).

Even though liver weight was lower in L200 and LT200 animals, histopathological analysis did not reveal any sign of hepatic lesion (data not shown). In spite of this, body and liver weight reduction can be considered an indicative of maternal toxicity, therefore, the dose of 200 mg/kg body weight of lapachol already presents signs of maternal toxicity, and can be considered the dose limit for assessing developmental toxicity (CHRISTIAN *et al.*, 2001).

Therefore, it is possible that the discrepancy regarding teratogenicity, reported by Almeida *et al.* (1988), and our previous works (GUERRA *et al.*, 1999; 2001) may be due to the fact that those authors exceeded the threshold of maternal toxicity.

Ovary weight, mean of corpora lutea per ovary, mean of embryo implantations in uterine horns as well as the implantation index were similar among the groups, suggesting that rats from all experimental groups had a similar number of ovulations, similar pattern of corpora lutea growing, and similar hormonal and biochemical profile, allowing the embryo to develop until implantation in the uterine cornua.

It could be noted that, even though a similar proportion of embryo implantation occurred among

all groups, the index of resorptions per experimental group was significantly higher in rats treated with 100 mg and 200 mg/kg body weight of lapachol ($p < 0.01$). Hence, it can be supposed that, after lapachol administration, a considerable number of implanted embryos were severely wounded, causing their death.

The ninth day post-coitum is a critical period for the rat embryo development, to the extent that the following structures can be observed: primordial heart, primitive intestine, appearance of somites and the beginning of neural tube closure (CHRISTIE, 1964; SCHNEIDER & NORTON 1979; MANSON & KANG, 1994; HILL, 2001; CHRISTIANSEN & MULAN 2003; CARMO *et al.*, 2004). During this period, embryo cells do not have the same capacity of differentiation as observed in the period of cleavage, making the recover of injured structures more difficult. In such a case, the occurrence of those injuries is more frequently observed when the toxic effect is generalized. When the teratogenic agent is specific, the occurrence of structural alterations of organs and systems is more common (LEMÓNICA, 1996; MOORE. & PERSAUD 2000).

The process of intra-uterine development can respond to a toxicant with embryo death, malformations and intra-uterine growth delay (CATALANO *et al.*, 1993; SULLIVAN *et al.*, 1993; MANSON & KANG 1994).

In group L200, the number of embryo deaths was very high (82.9%), 10 in 12 rats presented only resorptions when exposed to a hydroalcoholic solution of lapachol, and in group LT200, there were 100% resorptions, so embryo lethality can not be attributed to the known deleterious effect of alcohol.

Fetal body weight, one of the end points for assessing fetal toxicity (RYAN *et al.*, 1991), was significantly smaller in rats treated with 50 and 100 mg/kg body weight of lapachol (MAZONI 1998), when compared to the control group ($p < 0.05$), indicating that the drug induced intra-uterine growth delay. The above-mentioned data characterize the toxic effect of lapachol on embryo development.

When the administered drug holds a high teratogenic potential, malformations can be observed in the entire litter, with or without the occurrence of fetal deaths. However, in this work, this was not the case.

Embryotoxicity, another kind of response to

xenobiotics, consists on growth delay of surviving fetuses, associated with a high mortality index, without the occurrence of malformations. Such response is caused by alteration of fundamental cellular processes, like glycolysis, mitochondrial function and membrane integrity. These processes are common to all cells, leading to alterations in all embryo tissues (KHERA *et al.*, 1989; SULLIVAN, 1993; MANSON & KANG, 1994).

Lapachol is an antimitotic agent that inhibits mitochondrial oxidation and phosphorylation (SANTANA, 1968), antagonizes vitamin K reactions (DIGNEN & EBISUZAKI, 1997), or generates reactive oxygen species (MULLER *et al.*, 1999). All these effects are exerted regardless of the cell type, affecting all cells of the developing organism, which is in accordance with the results of the present work.

Considering the results obtained and the experimental model used, it is possible to conclude that lapachol was embryotoxic to the rats' fetuses and caused growth reduction. On the other hand, it did not cause fetal malformations, as it would be expected for a teratogen.

ACKNOWLEDGMENTS

The authors are thankful to Dr. Rita de Cássia da Silveira e Sá (Professor, Department of Biology, Federal University of Juiz de Fora) for helpful suggestions and for reviewing the English version of this manuscript; to Nathália Barbosa do Espírito Santo Borges (FAPEMIG). This work was supported in part by FAPEMIG CDS 952/02; FAPEMIG EDT 1879/02 and CNPq (Brazil).

REFERENCES

- ALMEIDA, E.R.; MELLO, A.C.; SANTANA, C.F.; FILHO, A.A.S. & SANTOS, E.R. 1988. The action of 2-hydroxy-3-(3-methyl-2-butenyl)-1,4-naphthoquinone (lapachol) in pregnant rats. *Revista Portuguesa de Farmácia* **28**: 21-23.
- AUSTIN, F.G. 1974. *Schistosoma mansoni* chemoprophylaxis with dietary lapachol. *The American Journal of Tropical Medicine and Hygiene* **23**: 412-419.
- BALASSIANO, I.T.; DE PAULO, S.A.; SILVA, N.H.; CABRAL, M.C. & CARVALHO, M.G.C. 2005. Demonstration of the lapachol as a potential drug for reducing cancer metastasis. *Oncology Reports* **13**: 329-233.
- CARMO, J.C.; PETERS, V.M. & GUERRA, M.O. 2004. Cronologia do desenvolvimento embrionário e fetal de ratos conforme a datação do início da prenhez. *Boletim do Centro de Biologia da Reprodução* **23**: 5-16.
- CATALANO, P.J.; SCHARFSTEIN, D.O.; RYAN, L.M.; KIMMEL, C.A. & KIMMEL, G.L. 1993. Statistical Model for Fetal Death, Fetal Weight, and Malformation in Developmental Toxicity Studies. *Teratology* **47**: 281-290.
- CHAHOU, I.; LIGENSA, A.; DIETZEL, L. & FAQI, A.S. 1999. Correlation between maternal toxicity and embryo/fetal effects. *Reproductive Toxicology* **13**: 375-381.
- CHRISTIAN, M.S. 2001. Test methods for assessing female reproductive and developmental toxicology. In: HAYES, A.W. *Principles and methods of toxicology*. 4th ed. Philadelphia, Taylor & Francis, p. 1301.
- CHRISTIANSEN, J. & MULAN, L.J. 2003. Endinburgh Mouse Atlas of Gene Expression. Appendix 4, Theiler Staging. Disponível em: <<http://genex.hgu.mrc.ac.uk/Documentation/Emage/Course/emage/Appendix4.html>> Acesso em: 1 Out. 2003.
- CHRISTIE, G.A. 1964. Developmental Stages in Somite and Post-somite Rat Embryos, Based on External Appearance, and Including some Features of the Macroscopic Development of the Oral Cavity. *Journal of Morphology* **114**: 263-283.
- DE ANDRADE-NETO, V.F.; GOULART, M.O.; DA SILVA FILHO, J.F.; DA SILVA, M.J.; PINTO, M. DO C.; PINTO, A.V. *et al.* 2004. Antimalarial activity of phenazines from lapachol, 2-lapachone and its derivatives against *Plasmodium falciparum* *in vitro* and *Plasmodium berghei* *in vivo*. *Bioorganic & Medicinal Chemistry Letters* **14**: 1145-1149.
- DIGNEN, R.D. & EBISUZAKI, K. 1997. The search for novel anticancer agents: a differentiation based assay and analysis of a folklore product. *Anticancer Research* **17**: 1027.
- DUARTE, D.S.; DOLABELA, M.F.; SALAS, C.E.; RASLAN, D.S.; OLIVEIRAS, A.B.; NENNINGER, A. *et al.* 2000. Chemical characterization and biological activity of *Macfadyena unguis-cati* (Bignoeaceae). *The Journal of Pharmacy and Pharmacology* **52**: 347-352.
- GUERRA, M.O.; MANZONI, A.S.; BRANDÃO, M.A. & PETERS, V.M. 1999. Interceptive effects of lapachol in rats. *Contraception* **60**: 305-307.
- GUERRA, M.O.; MAZONI, A.S.; BRANDÃO, M.A. & PETERS, V.M. 2001. Toxicology of lapachol in rats: embryoletality. *Brazilian Journal of Biology* **61**: 171-174.
- HILL, M. 2001. Rat Development, *in* UNSW Embryology. Disponível em: <<http://embryology.med.unsw.edu.au/OtherEmb/Rat.htm>> Acesso em: 20 set. 2005.
- KHERA, K.S. 1984. Maternal Toxicity - A Possible Factor in Fetal Malformations in Mice. *Teratology* **29**: 411-416.

- KHERA, K.S.; GRICE, H.C. & CLEGG, D.J. (ed.). 1989. **Current issues in Toxicology**. New York, Springer-Verlag, p. 9-12.
- LEMÔNICA, I.P. 1996. Embriofetotoxicidade. *In*: OGA, S. **Fundamentos de Toxicologia**. São Paulo, Atheneu, p. 85.
- LIMA, N.M.F.; CORREIA, C.S.; LEON, L.L.; MACHADO, G.M.; MADEIRA, M. DE F.; SANTANA, A.E.G. & GOULART, M. 2004. Antileishmanial activity of lapachol analogues. **Memórias do Instituto Oswaldo Cruz** 99(7): 757-761.
- LIMA, N.M.F.; DOS SANTOS, A.F.; PORFIRIO, Z.; GOULART, M.O. & SANT'ANA, A.E. 2002. Toxicity of lapachol and isolapachol and their potassium salts against *Biomphalaria glabrata*, *Schistosoma mansoni* cercariae, *Artemia salina* and *Tilapia nilotica*. **Acta Tropica** 83: 43-47.
- MANSON, J.M. & KANG, Y.J. 1994. Test methods for assessing female reproductive and developmental toxicology. *In*: HAYES, A.W. **Principles and methods of toxicology**. 3rd ed. New York, Raven Press, chap. 28, p. 989.
- MAZONI, A.S.B. 1998. **Avaliação do Potencial Teratogênico do Lapachol em Ratas Wistar**. (Monografia, Curso de Especialização em Fármacos e Produtos Naturais, Faculdade de Farmácia e Bioquímica, Universidade Federal de Juiz de Fora) 28p.
- MOORE, K.L. & PERSAUD, T.V.N. 2000. **Embriologia Clínica**. 6. ed. Rio de Janeiro, Guanabara Koogan, p. 543.
- MULLER, K.; SELLMER, A. & WIEGREBE, W. 1999. Potential antipsoriatic agents: lapachol compounds as potent inhibitors of HaCaT cell growth. **Journal of Natural Products** 62: 1134-1136.
- SCHNEIDER, B.F. & NORTON, S. 1979. Equivalent Ages in Rat, Mouse and Chick Embryos. **Teratology** 19: 273-278.
- SULLIVAN, F.M. 1993. Impact of the Environment on Reproduction from Conception to Parturition. **Environmental Health Perspectives** 101: 13-18.
- RYAN, L.M.; CATALANA, P.J.; KIMMEL, C.A. & KIMMEL, G.L. 1991. Relationship Between Fetal Weight and Malformation in Developmental Toxicity Studies. **Teratology** 44: 215-223.
- SACAU, E.P.; ESTEVEZ-BRAUN, A.; RAVELO, A.G.; FERRO, E.A.; TOKUDA, H. & MUKAINAKA, T. 2003. Inhibitory effects of lapachol derivatives on epstein-barr virus activation. **Medicinal Chemistry** 11: 483-488.
- SANTANA, C.F.; LIMA, O.G.; D'ALBUQUERQUE, I.L.; LACERDA, A.L. & MARTINS, D.G. 1968. Observações sobre as propriedades antitumorais e toxicológicas do extrato do líber e de alguns componentes do cerne do pau-dárco (*Tabebuia avellanedae*). **Revista do Instituto de Antibióticos** 8: 89-94.

Recebido: 22/11/2007

Revisado: 12/01/2008

Aceito: 12/02/2008

