

# THE USE OF THE PAPANICOLAOU STAIN TO ROUTINE HISTOLOGICAL EXAMINATION: TEACHING THE BASIC MICROSCOPY OF SQUAMOUS CELL CARCINOMA

*O USO DA COLORAÇÃO DE PAPANICOLAOU PARA EXAME HISTOLÓGICO DE ROTINA: ENSINO DA MICROSCOPIA BÁSICA DE CARCINOMA DE CÉLULAS ESCAMOSAS*

*Pietro Mainenti\**

## ABSTRACT

**Introduction:** The understanding of microscopy classes is imperative to the student in human pathology. **Objective:** To prepare the student to observe and understand, through tinctorial recognition, the main histologic features of Papanicolaou-stained well-differentiated carcinomas. **Methods:** A selected case of a well-differentiated carcinoma of the tongue was used for a Papanicolaou stain. **Results:** The Papanicolaou-stained slides showed, basically, basal cells in a faint to a dark blue color. The stratum spinosum stained light pink to a faint blue-green and the keratin layer and the keratin pearls stained bright orange. The connective tissue stained light green. **Conclusion:** The use of Papanicolaou stain was found very convenient as the beginner in histopathology can perform a ready identification of the well-differentiated squamous cell carcinoma aspects.

## KEYWORDS

Papanicolaou. Staining. Histopathology. Squamous cell carcinoma.

## RESUMO

A compreensão da microscopia é imperativa para o estudante em patologia humana. **Objetivo:** preparar o aluno para observar e entender, através do reconhecimento tintorial, as principais características histológicas dos carcinomas bem diferenciados corados com Papanicolau. **Métodos:** foi utilizado um caso selecionado de carcinoma bem diferenciado da língua para uma coloração de Papanicolau. **Resultados:** As lâminas coradas com Papanicolau mostraram, basicamente, células basais azul escuro a fraco. O estrato espinhoso corou-se em rosa claro até um fraco azul-esverdeado e a camada de queratina e as pérolas de queratina em laranja brilhante. O tecido conjuntivo se corou em verde. **Conclusão:** o uso da coloração Papanicolau foi muito conveniente, já que o iniciante na histopatologia pode realizar uma pronta identificação dos aspectos do carcinoma de células escamosas bem diferenciados.

## PALAVRAS-CHAVE

Papanicolaou. Coloração. Histopatologia. Carcinoma de células escamosas.

---

## 1 INTRODUCTION

The study of microcopy by graduate students in Medicine and other health sciences is very important. The squamous cell carcinoma is a neoplasm related, mainly, to tobacco and alcohol abuse (KAMINAGAKURA et al., 2016). Acharya et al. (2016) stated that carcinoma is the eight most common malign neoplasm in the World. According to Loganathan et al. (2017), tongue malignancies account for 90% of carcinomas in the oral cavity.

---

Correspondence Author: Prof. Pietro Mainenti. pietromainenti@terra.com.br. Universidade Presidente Antônio Carlos, Av. Juiz de Fora, 1100, Granjas Bethânia, Juiz de Fora, Minas Gerais, Brazil, Postal Code: 36048-000. Phone: +553221022103.

Professor, MSc, PhD, Department of Pathology, Faculdade de Medicina de Juiz de Fora, Universidade Presidente Antônio Carlos, Juiz de Fora, Minas Gerais, Brazil

Received: 05/2017

Accepted: 07/2017

The histopathology of the squamous cell carcinoma is of paramount importance to understand the disease in all levels. Graduate students may have some difficulties to deal with carcinoma features during microscopy classes.

This paper aims to present the Papanicolaou stain in paraffin-block tissue sections of a well-differentiated squamous cell carcinoma of the tongue, as a tool in microscopy classes.

## 2 METHODS

The slides refer to a selected case of a well-differentiated carcinoma of the tongue. The use of information is in accord with ethical standards once the images cannot identify the patient.

The slides were cut in 5µm-thick sections for Hematoxylin and Eosin and for Papanicolaou stain. The slides for Hematoxylin and Eosin were stained for routine histological examination. For the Papanicolaou stain, the author used the following method:

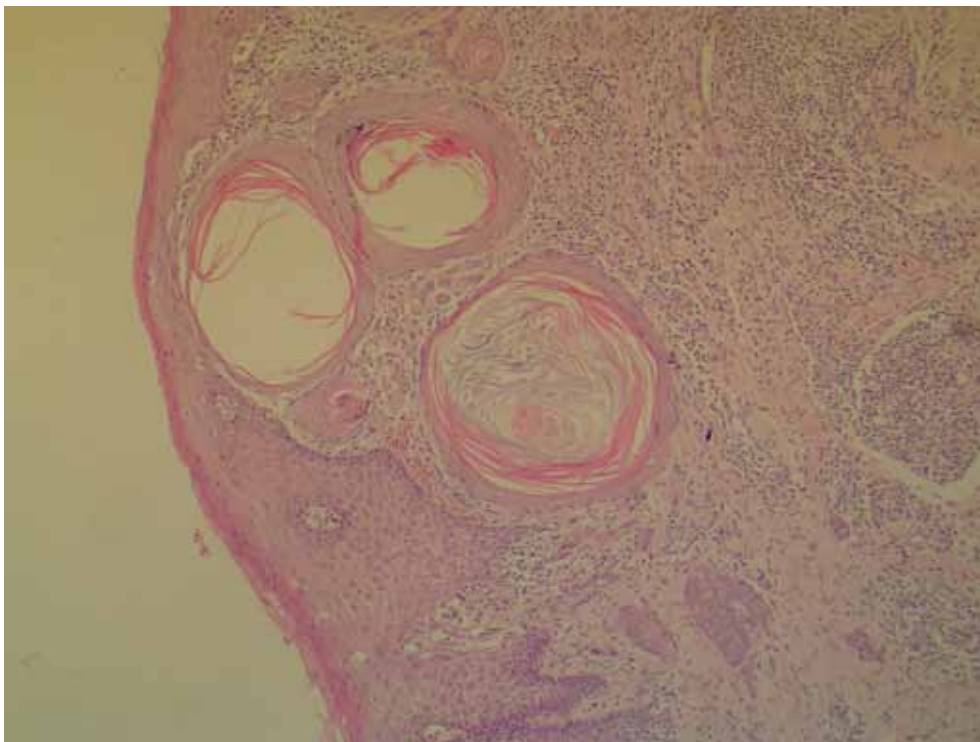
1. Deparaffinize in xylene;
2. Hydrate through one change in alcohols to distilled water;
3. Stain in Harris's hematoxylin for 3 minutes;

4. Rinse in tap water for 3 minutes;
5. Rinse in absolute alcohol (12 times);
6. Stain in Orange for 3 minutes;
7. Rinse in absolute alcohol (12 times);
8. Stain in EA (eosin) for 3 minutes;
9. Rinse in absolute alcohol (12 times);
10. Clear in xylene (12 times);
11. Mount.

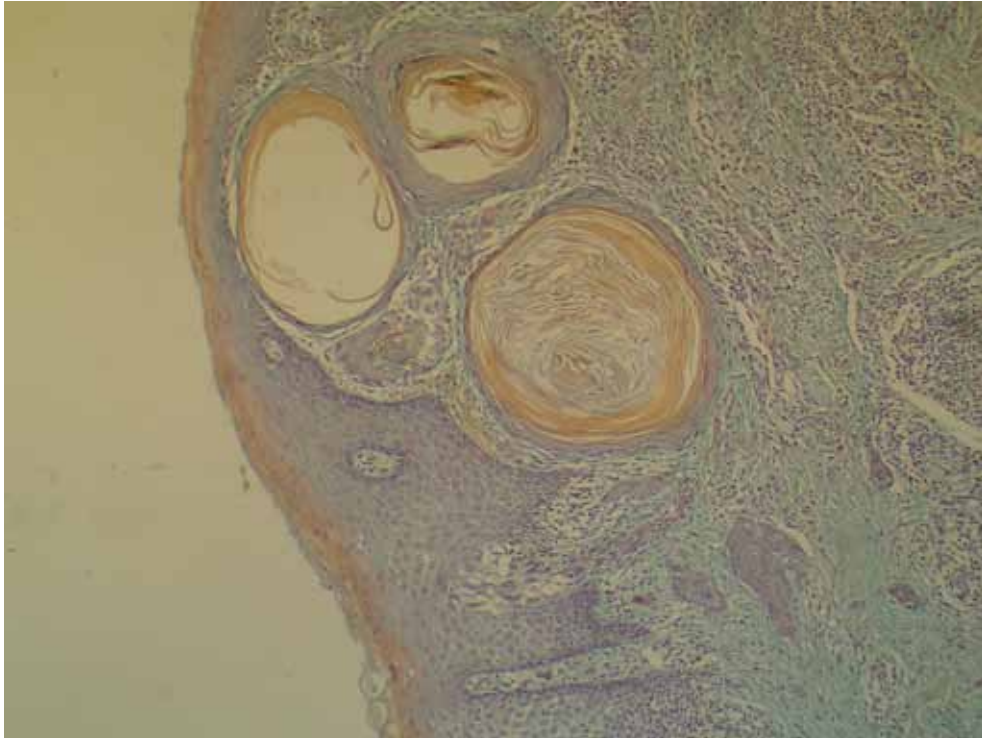## 3 RESULTS

The Hematoxylin and Eosin slides showed usual attributes (Figure 1).

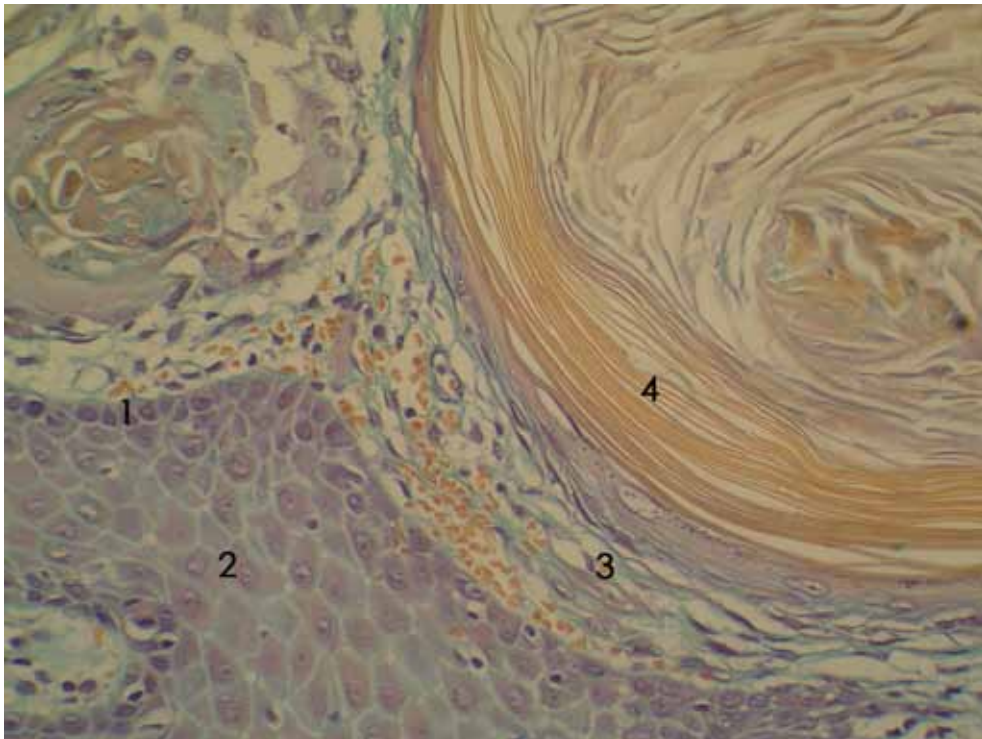
The Papanicolaou method disclosed the normal epithelial cells with different chromatic features. The basal cells were darker than the others layers. The nuclei were dark blue and the cytoplasm varied from a faint to a dark blue. The stratum spinosum cells stained light pink to a faint blue-green. The desmosomes stained green. The superficial layers stained bright orange. The connective tissue stained light green and disclosed some keratin pearls. The keratin pearls stained bright orange, the inner rim cells stained light pink and the outer rim cells stained pink/ blue with nucleus in dark blue (Figures 2 and 3).



**Figure 1:** Routine Hematoxylin and Eosin. 100x magnification.



**Figure 2:** Panoramic view of the well-differentiated squamous cell carcinoma. Papanicolaou stain, 100x magnification.



**Figure 3:** Well-differentiated squamous cell carcinoma in detail. 1-basal cell layer, 2-stratum spinosum, 3-connective tissue and 4-keratin pearls. Papanicolaou stain, 400x magnification.

## 4 DISCUSSION

According to Loganathan et al. (2017), an approximate number of 500,000 cases of oral cancer occur, every year, around the globe. The tobacco use and HPV infection were related as main causes of carcinoma development in the oral area (KAMINAGAKURA et al., 2016; ACHARYA et al., 2016; LOGANATHAN et al., 2017; HASHIBE; STURGIS, 2013). The tongue is the deadliest site in the mouth (RODRIGUES et al., 2014) with a high incidence of relapse due to lymphatic spread (LOGANATHAN et al., 2017). Most carcinomas are alike in terms of the histology, regardless the region. Due to the importance of the tongue cancer, the specimen used, in the present research, was a well-differentiated carcinoma in order to present the first step in the recognition of the basic aspects of the tumor to the graduate students.

Staining histologic preparations using Papanicolaou is not a novel method. In 1956, Johnson and Klein (1956) used the Papanicolaou stain to study, mainly, keratinized epithelial tissues. They concluded that the method presented sharply defined nuclear material and better cytoplasmic differentiation when comparing Hematoxylin and Eosin stains. Mainenti et al. (2008) alluded to the same observation after applying Papanicolaou stain to rat salivary gland squamous cell carcinomas induced by 7,12-Dimethylbenz[a]anthracene (DMBA), in a carcinogenesis process. They considered the stain an interesting method due to the availability in most laboratories, the sharp contrasts in color and because it yields nuclear detail such as mitosis (MAINENTI et al., 2008). The results showed in the current paper are in tune with the concepts in the literature.

The staining method preconized by Johnson and Klein (1956) used 6, 5 and 2.5 minutes in Hematoxylin, Orange and EA, in this order. The authors concluded that the method was very helpful in the identification of keratin. The keratin stained bright orange when was superficial. The intermediate epithelial layers stained deep red and the basal cells and connective tissue stained green (JOHNSON; KLEIN, 1956). In this research, the staining method adopted was different from the literature. The staining in Hematoxylin, Orange and EA took 3 minutes. The method disclosed similar results in regard of the keratin (bright orange) and the connective tissue (green). However, the stratum spinosum (light pink to a faint blue) and the basal layer (faint to a dark blue) stained differently.

The difference between the literature and our results, apparently, could be addressed to the variation in the use of the dyes. However, the tissue samples were different. The present research used neoplastic tissue instead of non-tumoral samples. According to Demay (1996), the cyanophilia is due to the presence of ribosomes in neoplastic cells. The epithelial cells vary from blue-green to pale orange and intense orange as the cells progress from the basal to the keratin layers (JOHNSON; KLEIN, 1956). The color patterns presented are the same as the results showed in this research.

## 5 CONCLUSION

The use of Papanicolaou stain in paraffin-block tissue sections was found to be helpful in graduate microscopy classes in the author's personal experience. Although not a routine procedure it is interesting to teach the first steps in the recognition of keratinization, in well-differentiated carcinomas. The tinctorial differences between structures can be readily understood by the student. However, it does not supersede the use and the study of the Hematoxylin and Eosin stain.

## 6 REFERENCES

- ACHARYA, S.; RAI, P.; HALLOKERI, K.; ANEHOSUR, V.; KALE, J. Serum lipid profile in oral squamous cell carcinoma: alterations and associations with some clinicopathological parameters and tobacco use. *Int J Oral Maxillofac Surg.*, v. 45, n. 713, p. 713-720, 2016.
- LOGANATHAN, P.; SAYAN, A.; HSU, D. W. K.; PARANEETHARAN, S.; ILANKOVAN, V. Squamous cell carcinoma of the anterior tongue: is tumor thickness an indicator for cervical metastasis? *Int J Oral Maxillofac Surg.*, v. 46, p. 407-412, 2017.
- HASHIBE, M.; STURGIS, E. M. Epidemiology of oral cavity and oropharyngeal carcinomas: controlling a tobacco epidemic while a human papillomavirus epidemic emerges. *Otolaryngol Clin North Am.*, v. 46, p. 507-520, 2013.
- RODRIGUES, P. C.; MIGUEL, M. C.; BAGORDAKIS, E.; FONSECA, F. P.; DE AQUINO, S. N.; SANTOS-SILVA, A. R. et al. Clinicopathological prognostic factors of oral tongue squamous cell carcinoma: a retrospective study of 202 cases. *Int J Oral Maxillofac Surg.*, v. 43, p. 795-801, 2014.
- JOHNSON, P. L.; KLEIN, M. N. Application of the Papanicolaou stain to paraffin sections. *Stain Technol.*, v. 31, p. 223-225, 1956.

MAINENTI, P.; SOUSA, F. A. C. G.; BOLANHO, A.; ROSA, L. E. B. Uso da coloração de Papanicolaou em carcinomas induzidos por DMBA em glândulas salivares de ratos. *Braz Oral Res.*, v. 22, p. 262, 2008.

DEMAY, R. M. Papanicolaou stain. In: DEMAY, R. M. (Ed.). *The art & science of Cytopathology: exfoliate cytology*. Chicago: ASCP Press, 1996. p.13-28.

KAMINAGAKURA, E.; CARIS, A.; COUTINHO-CAMILO, C.; SOARES, F. A.; TAKAHAMA-JÚNIOR, A.; KOWALSKI, L. P. Protein expression of CYP1A1, CYP1B1, ALDH1A1, and ALDH2 in young patients with oral squamous cell carcinoma. **Int J Oral Maxillofac Surg.**, v. 45, n. 706, p. 706-712, 2016.